



# Intravenous Fibrinolysis for Central Retinal Artery Occlusion

## A Cohort Study and Updated Patient-Level Meta-Analysis

Brian Mac Grory, MB BCh BAO, MRCP; Alex Nackenoff, PhD; Sven Poli, MD; Martin S. Spitzer, MD; Max Nedelmann, MD; Benoit Guillon, MD; Cécile Preterre, MD; Celia S. Chen, MBBS, PhD; Andrew W. Lee, MBBS, MPH; Shadi Yaghi, MD; Christoph Stretz, MD; Idrees Azher, MD; John Paddock, MD; Tatiana Bakaeva, MD PhD; David M. Greer, MD, MA; Julie G. Shulman, MD; Robert G. Kowalski, MBBCh, MS; Patrick Lavin, MB BCh BAO, MRCP; Eva Mistry, MBBS; Kiersten Espaillet, APRN; Karen Furie, MD, MPH; Howard Kirshner, MD, PhD; Matthew Schrag<sup>1</sup>, MD, PhD

**BACKGROUND AND PURPOSE:** Central retinal artery occlusion results in sudden, painless, usually permanent loss of vision in the affected eye. There is no proven, effective treatment to salvage visual acuity and a clear, unmet need for an effective therapy. In this work, we evaluated the efficacy of intravenous tissue-type plasminogen activator (IV alteplase) in a prospective cohort study and an updated systematic review and meta-analysis.

**METHODS:** We enrolled consecutive patients with acute central retinal artery occlusion within 48 hours of symptoms onset and with a visual acuity of <20/200 from January 2009 until May 2019. The primary outcomes were safety and functional visual acuity recovery. We compared rates of visual recovery between those treated with alteplase within 4.5 hours of symptom onset to those who did not receive alteplase (including an analysis restricted to untreated patients presenting within the window for treatment). We incorporated these results into an updated systematic review and patient-level meta-analysis.

**RESULTS:** We enrolled 112 patients, of whom 25 (22.3% of the cohort) were treated with IV alteplase. One patient had an asymptomatic intracerebral hemorrhage after IV alteplase treatment. Forty-four percent of alteplase-treated patients had recovery of visual acuity when treated within 4.5 hours versus 13.1% of those not treated with alteplase ( $P=0.003$ ) and 11.6% of those presenting within 4 hours who did not receive alteplase ( $P=0.03$ ). Our updated patient-level meta-analysis of 238 patients included 67 patients treated with alteplase within 4.5 hours since time last known well with a recovery rate of 37.3%. This favorably compares with a 17.7% recovery rate in those without treatment. In linear regression, earlier treatment correlated with a higher rate of visual recovery ( $P=0.01$ ).

**CONCLUSIONS:** This study showed that the administration of intravenous alteplase within 4.5 hours of symptom onset is associated with a higher likelihood of a favorable visual outcome for acute central retinal artery occlusion. Our results strongly support proceeding to a randomized, placebo-controlled clinical trial.

**Key Words:** ischemic stroke ■ retinal artery occlusion ■ tissue-type plasminogen activator ■ treatment ■ visual acuity

Central retinal artery occlusion (CRAO) interrupts blood supply to the retina, leading to sudden painless vision loss. It is a form of acute ischemic stroke as recognized by the American Heart Association.<sup>1</sup> Acute

CRAO may be amenable to treatment with intravenous fibrinolytic therapy, and this concept has been reported since the 1960s initially with streptokinase<sup>2</sup> and then urokinase<sup>3</sup> before the use of recombinant tissue-type

Correspondence to: Matthew Schrag MD, PhD, Department of Neurology, Vanderbilt University School of Medicine, Medical Research Bldg III, Suite 6160 (Office 6158C), 465 21st Ave S, Nashville, TN 37240. Email [matthew.schrag@vanderbilt.edu](mailto:matthew.schrag@vanderbilt.edu)

This manuscript was sent to Gregory W. Albers, MD, Guest Editor, for review by expert referees, editorial decision, and final disposition.

The Data Supplement is available with this article at <https://www.ahajournals.org/doi/suppl/10.1161/STROKEAHA.119.028743>.

For Disclosures, see page 2025.

© 2020 American Heart Association, Inc.

Stroke is available at [www.ahajournals.org/journal/str](http://www.ahajournals.org/journal/str)

plasminogen activator (IV alteplase) became more widespread for cerebral stroke after the results of the NINDS trial<sup>4</sup> However, its use is not reference in any professional stroke guidelines and there has only been a single, small, randomized-controlled trial.<sup>5</sup> In 2015, we reported improved visual acuity outcomes in patients treated with intravenous fibrinolysis (urokinase, streptokinase, or alteplase) within 4.5 hours of the onset of vision loss in a subject-level meta-analysis.<sup>6</sup> In that study, we found that conventional treatments like anterior chamber paracentesis and ocular massage surprisingly reduced the probability of recovery of visual acuity to less than half that of no treatment, that is, the natural history. However, fibrinolysis increased the rate of recovery from 17.7% to almost 50% if initiated within 4.5 hours of onset, although there did not seem to be a benefit beyond 4.5 hours. Subsequently, we polled academic medical centers in the United States to determine the frequency of use of IV fibrinolytic agents for acute CRAO and found 53% of respondents indicated they currently treat selected patients with acute CRAO with IV alteplase.<sup>7</sup> These 2 studies form the foundation for the current work. We evaluated the feasibility and efficacy of administering IV alteplase for treatment of acute CRAO in an observational cohort using the established dosing protocols for acute ischemic stroke. We incorporated this data with results from our prior analysis and new subject-level data from 3 additional observational case series<sup>8–10</sup> and one randomized, placebo-controlled clinical trial<sup>5</sup> to generate the largest meta-analysis to date of the efficacy of IV alteplase for acute CRAO.

## METHODS

### Observational Cohort Study

The data that support the findings of this study are available from the corresponding author upon reasonable request. This study was approved by the institutional review boards of Vanderbilt University Medical Center (approval #160767) and of Rhode Island Hospital (approval #1242500) and the observational cohort includes only patients from these institutions. The requirement for written, informed consent was waived. Inclusion criteria were adults presenting with sudden, painless vision loss, visual acuity of 20/200 or less upon arrival in the emergency department (ED), best corrected visual acuity of 20/100 or better in the affected eye before the CRAO, and no other ophthalmologic or neurological diagnosis better accounting for the vision loss. Patients were included from January 2009 to June 2019. Administration of IV alteplase in a timely manner requires a well-designed clinical work-flow, so we implemented a protocol for rapid, systematic evaluation of acute CRAO similar to the “stroke code” system, incorporating an immediate dilated ophthalmologic evaluation. Patients presenting within 6 hours of symptoms onset and who did not have contraindications for intravenous fibrinolysis (including active bleeding, recent stroke or hemorrhage, or use of anticoagulation) were offered treatment with IV alteplase at a dose of 0.9 mg/kg (with 10% administered as a bolus and the remainder infused over 1 hour). Informed consent was obtained

before treatment. The time interval for IV alteplase treatment was reduced to 4.5 hours in July 2015 in response to a meta-analysis of observational data suggesting a lack of benefit when fibrinolysis was administered in the 4.5 to 6 hour time window.<sup>6</sup> Patients were admitted to the stroke unit for intensive neuromonitoring, systematic risk factor screening, and implementation of secondary prevention strategies. An illustrative protocol is shown in Figure 1. A comparison between our protocol for IV alteplase administration, the current FDA labeling for alteplase for acute stroke treatment, and the ECASS III<sup>11</sup> trial protocol is included as Table I in the [Data Supplement](#). Visual acuities are reported in the conventional Snellen scale, but statistical analysis of visual acuity was performed using logMAR equivalencies<sup>12</sup> as this is closer to a linear scale. The time from symptom onset to arrival in the ED and the time until the first contact with any medical provider were documented. We defined visual acuity “recovery” as a dichotomized outcome representing functional recovery of vision with a final visual acuity of 20/100 or better. Because all patients in this study presented with a visual acuity of 20/200 or worse, the smallest improvement meeting this threshold was 0.3 on the logMAR scale (3 lines on the Snellen chart). Prior studies often used any improvement of 0.3 on the logMAR scale to indicate recovery, so we also report this statistic. The significance of differences in visual acuity recovery rate and all other dichotomized outcomes was assessed with the (N-1)  $\chi^2$  test.<sup>13</sup> To account for the higher rate of spontaneous recovery among patients presenting earlier within the time window since last known well, we performed an additional analysis on patients who presented within the 4-hour time window but did not receive alteplase. The 4-hour window was chosen under the assumption that it takes at least 30 minutes to execute the acute stroke protocol including neuroimaging, laboratory testing, and preparing alteplase (and as such, these patients could feasibly have received alteplase). We incorporated additional patients from a second site (Rhode Island Hospital) in this analysis of time-matched controls to improve statistical power and generalizability. None of the patients included in this observational study were included in our prior meta-analysis.<sup>6</sup> Clinical characteristics are reported using descriptive statistics and compared between the 2 groups using an unpaired Student *t*-test for continuous data and  $X^2$  test for categorical data.

### Subject-Level Meta-Analysis

The systematic review and meta-analysis were performed in accordance with the Meta-Analysis of Observational Studies in Epidemiology guidelines.<sup>14</sup> This study is registered with PROSPERO (CRD42020145734). We performed an updated meta-analysis from August 1, 2014 until May 23, 2019 using the following search string: “retinal artery occlusion” OR “retinal ischemia” AND “thrombolysis” OR “fibrinolysis” OR “tissue plasminogen activator” OR “streptokinase” OR “urokinase” OR “tenecteplase.” No limitations on language were placed. We excluded studies with fewer than 5 patients to reduce the risk of selection bias, as well as studies with insufficient detail concerning visual acuity outcomes. In studies where patient-level data were not available, the corresponding author was contacted directly. Patient-level data was shared in a de-identified fashion and using arbitrary identifiers. The methodology is described in more detail in a previous study.<sup>6</sup> We initially performed an analysis including all thrombolytic agents (alteplase, streptokinase, and urokinase), and this section includes all the

Acute CRAO management algorithm:	
<b>Triage:</b>	<ul style="list-style-type: none"> <li>- Patients presenting with painless, sudden or stuttering loss of all or nearly all vision in one or both eyes without another clear cause will be referred to the general emergency department as a CODE STROKE and will be managed jointly by a neurologist and ophthalmologist.</li> <li>- If the initial presentation is to an ophthalmology clinic, the dilation of the eyes should be initiated and the patient urgently transferred to the emergency department without further evaluation in the clinic.</li> <li>- If evaluated by Telemedicine, the decision to offer thrombolytic treatment to qualified patients prior to transfer is based on the treating physicians' assessments of local resources to accurately diagnose CRAO and exclude important mimics.</li> </ul>
<b>Evaluation:</b>	<ul style="list-style-type: none"> <li>- Emergent (preferably dilated) funduscopic examination. Fluorescein angiography or ocular doppler sonography may be obtained as adjunctive evaluations, but should not slow treatment.</li> <li>- Labs: obtain complete blood count, creatinine, PT/INR, aPTT, erythrocyte sedimentation rate, C-reactive protein, troponin, LDL and glycosylated hemoglobin fraction on the initial encounter.</li> <li>- Imaging: CT head, ideally with CT angiogram of the head and neck.</li> </ul>
<b>Treatment:</b>	<ul style="list-style-type: none"> <li>- High-flow oxygen for all patients within 24 hours of onset. Discontinue after 6 hours if no improvement.</li> <li>- Offer intravenous fibrinolysis if CRAO is <b>the most likely diagnosis</b>, visual acuity is 20/200 or worse within 4.5 hours of onset and there are no contraindications. Verbal consent will be obtained from the patient after discussion of risks of benefits. Administer 0.9mg/kg tPA, 10% as a bolus, the remainder over 1 hour. Blood pressure not to exceed 180/100 during treatment.</li> <li>- Avoid ocular massage, anterior chamber paracentesis, hemodilution or carbogen inhalation.</li> <li>- If intra-ocular pressure is elevated, it should be treated with appropriate topical or systemic agents.</li> <li>- All patients with CRAO should be given appropriate antithrombotic therapy, typically aspirin and/or clopidogrel (delayed 24 hours if tPA is administered) and high-intensity statin therapy if LDL &gt;100.</li> <li>- If either ESR or CRP is elevated of 40, the patient has any clinical stigmata of temporal arteritis (absent temporal pulses or jaw claudication) AND there is minimal suspicion for infective endocarditis or other systemic infection, the patients should be urgently treated with 1g solumedrol IV. In the event of bilateral CRAO, high-dose steroid treatment should be strongly considered. The diagnosis of arteritic CRAO should be confirmed by temporal artery biopsy and/or fluorescein angiography and appropriate long-term treatment based on this evaluation. <i>[Note – ESR/CRP will be markedly elevated in the setting of malignancy, chronic infection or dialysis and may be falsely low in the setting immunodeficiency or immunosuppression; they should be interpreted with caution in these settings.]</i></li> </ul>
<b>Contraindications to thrombolysis:</b>	<ul style="list-style-type: none"> <li>- A stroke or serious head injury within the prior 3 months.</li> <li>- Severe uncontrollable hypertension, systolic blood pressure &gt;185 or diastolic &gt;110.</li> <li>- Bleeding disorder with INR &gt;1.7, elevated aPTT or platelet count &lt;100,000.</li> <li>- On anticoagulation with INR &gt;1.7 or elevated aPTT, or within 48 hours of the last dose of a novel oral anticoagulant (24 hours for apixaban). <i>[Prophylactic doses of heparin or enoxaparin, aspirin or clopidogrel use are NOT contraindications.]</i></li> <li>- Life-threatening spontaneous bleeding event within 90 days.</li> <li>- Prior intracranial hemorrhage, intracranial neoplasm, arteriovenous malformation or large, uncontrolled aneurysm.</li> <li>- Non-compressible vessel puncture or lumbar puncture within 7 days, major non-compressible surgical site within 90 days.</li> <li>- Pregnant or within the puerperium.</li> <li>- Rapidly improving symptoms</li> <li>- Known or suspected bacterial endocarditis</li> <li>- Evidence of vitreal hemorrhage, retinal detachment or large retinal hemorrhage.</li> <li>- Poor baseline visual acuity in the affected eye from any cause, e.g. macular degeneration, previous ischemic optic neuropathy, etc.</li> </ul>
<b>Secondary prevention:</b>	<ul style="list-style-type: none"> <li>- Obtain vascular imaging of the head and neck including the arch of the aorta to the intracranial vessels with surgical consultation for severe disease.</li> <li>- Obtain EKG and monitor on telemetry for 24 hours. Obtain serial cardiac ischemia markers if appropriate. Consider 14 – 30 days of cardiac event monitoring if no clear cause for the CRAO is identified to screen for atrial fibrillation.</li> <li>- Obtain MRI brain if no contraindications to evaluate for stroke.</li> <li>- Obtain echocardiogram with agitated saline study to evaluate for intracardiac shunting.</li> <li>- For young patients without a clear etiology for CRAO, obtain trans-esophageal echocardiogram and hypercoagulable state screening.</li> <li>- Appropriate risk-factor modification should be undertaken including adjustment of antihypertensive, lipid lowering and antihyperglycemic medications as appropriate, screening for sleep apnea, coaching on smoking cessation and education on optimal cardiovascular lifestyle choices.</li> </ul>

**Figure 1. Illustrative protocol for emergent treatment of central retinal artery occlusion.**

subjects from our prior meta-analysis as well as relevant studies that have been published since 2015.<sup>6</sup> We then performed an analysis restricted to alteplase alone and thus only two studies from our prior meta-analysis were included (Kattah et al<sup>15</sup> and Hattenbach et al<sup>16</sup>). Subject level data were reviewed for harmonization, and subjects with incomplete data, confounding medical illnesses (eg, occipital lobe stroke), or who did not meet the inclusion criteria for our cohort were censored. Studies were combined in the meta-analysis using a random-effects model weighted by the inverse of variance using the MIX1.7 software, validated by JASP. Linear regression of combined, subject-level visual acuity outcomes was performed in R.

## RESULTS

### Observational Cohort Study

We enrolled 112 patients with acute CRAO. Twenty-five patients (22.3% of the cohort) were treated with IV

alteplase, of whom 16 (14.3%) were treated within 4.5 hours of time last known well. Of patients presenting in the 4.5–6 hour time window, 8 out of 13 were treated with IV alteplase. Demographics for the primary study cohort are in Table; unadjusted, subject level outcomes are shown in Figure 2A and 2B. Patients treated with alteplase presented to the ED earlier ( $P=0.008$ ). They were also older ( $P=0.014$ ) and had a lower visual acuity on presentation ( $P=0.026$ ) compared with the patients who did not receive alteplase ( $P=0.026$ ). One patient developed CRAO after administration of alteplase for cerebral stroke and was excluded. The median time to arrival in the ED after onset of symptoms for all patients with acute CRAO was 8.0 hours (interquartile range, 5.0–18.3), but the median time to initial contact with any provider was 4 hours after onset (interquartile range, 1.5–12; Table). One patient had an asymptomatic intracerebral hemorrhage after alteplase treatment, which appeared

**Table. Clinical Characteristics of Patients With Acute CRAO**

Clinical Features (n=112)*	All Cases (SD Unless Indicated) (n=112)	Alteplase Within 4.5 h (n=16)	Standard of Care (n=87)	P Value
Age (mean, SD)	65.5±13.0	73.12±11.9	64.5±12.8	0.014
% female	46.4%	37.5%	46.0%	0.61
% right sided	52.8%	64.3%	54.2%	0.52
Hypertension	59.8%	68.8%	57.5%	0.57
Hyperlipidemia	51.1%	50%	54%	0.98
Diabetes mellitus	22.3%	18.8%	20.7%	1
Coronary artery disease	17%	18.8%	14.9%	0.99
Atrial fibrillation	12.5%	6.25%	13.8%	0.67
Smoking	8.9%	12.5%	9.2%	1
Time to presentation in ED (median, IQR)	8.0 h (5.0–18.3)	2.6 h (2.0–3.3)	11.0 h (7.0–27.0)	0.008
Time to first contact with any provider (median, IQR)	4.0 h (1.5–12)	1.0 h (0.7–1.3)	6.6 h (2.5–14.9)	0.04
Presenting visual acuity (logMAR)†	HM (2.2±0.6)	LP (2.5±0.3)	HM (2.1±0.6)	0.026
Final visual acuity (logMAR)†	CF (1.8±0.6)	20/600 (1.6±1)	CF (1.9±0.9)	0.076
% with clinical recovery‡	16.5%	43.8%	13.1%	0.009
Presenting intraocular pressure	15.2 mm Hg±3.8	16.75±3.2	15.1±4.0	0.41
Erythrocyte sedimentation rate	28±25.6	25.5±30.4	27.6±23.6	0.78
C-reactive protein	19.0±51.3	21.7±58.3	19.5±52.3	0.898
Percent with either ESR or CRP >50	22.4%	8.3%	23.9%	0.45
Platelet count	228±70.1	201±60.9	230.3±72.9	0.16
Hemoglobin A1c fraction	6.0%±1.0	6.2%±1.3	5.9±1.0	0.46
Low-density lipoprotein level	104±43.6	99.3±40.2	105.2±45.7	0.64
Presenting blood pressure (systolic)	156.0 mm Hg±27.5	162.9±24.8	154.2±27.7	0.26
Presenting blood pressure (diastolic)	85.9 mm Hg±19.4	91.2±25.6	84.6±18.6	0.23
Hypertensive crisis (SBP >180 or DBP >100)	33.6%	33.3%	32.5%	1
Funduscopy examination findings				
Emboli	9.9%	6.6%	11.5%	0.93
Retinal whitening	70.9%	50%	72.5%	0.28
Optic nerve head pallor or edema	30.9%	25.0%	29.7%	0.48
Arterial narrowing or "boxcarring"	67.2%	57.1%	70.0%	1
"Cherry red" macula	76.0%	64.2%	76.5%	0.59
Relative afferent papillary defect	87.6%	86.7%	86.4%	1

DBP indicates diastolic blood pressure; ED, emergency department; ESR, erythrocyte sedimentation rate; IQR, interquartile range; and SBP, systolic blood pressure.

\*Note: 8 cases included in column 1 were treated with alteplase between 4.5 and 6 h after onset and 1 case developed CRAO after treatment with alteplase for stroke; these are not shown in the final 2 columns.

†LogMAR >1.7 up to counting fingers (CF) recorded as 2.0, hand movement (HM) as up to 2.3, light perception (LP) as up to 2.6, and no light perception as up to 2.9.

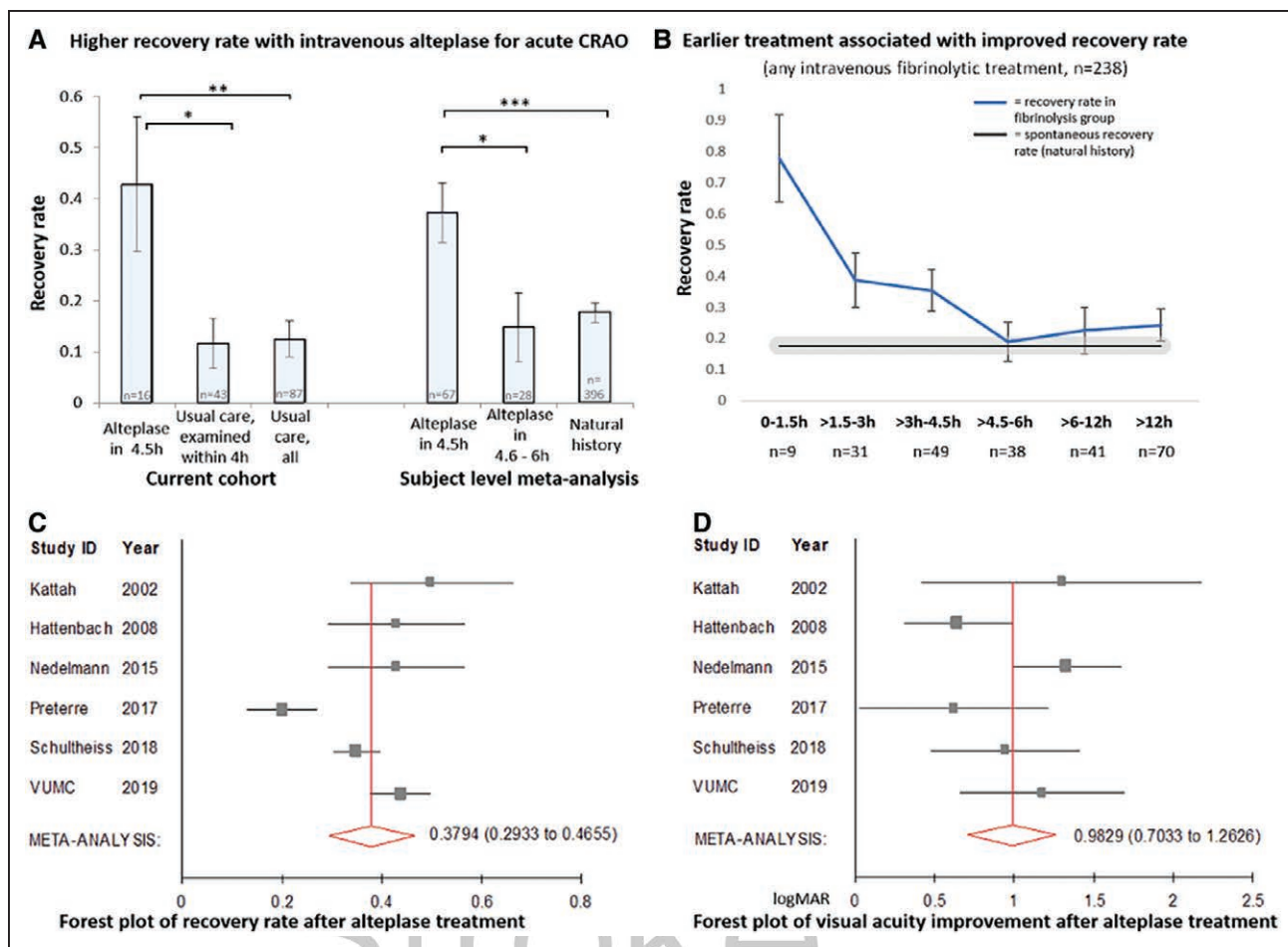
‡Clinical recovery defined as final logMAR ≤0.7 (20/100).

to be related to previously undiagnosed cerebral amyloid angiopathy. There were no other adverse events. Forty-four percent (43.8%) of patients treated with alteplase had recovery of visual acuity when treated within 4.5 hours versus only 13.1% of patients not treated with alteplase ( $P=0.003$ ; Figure 2A). Forty-three patients (25 from VUMC and 15 from RIH) presented within 4 hours and did not receive alteplase and achieved visual recovery 11.6% of the time ( $P=0.03$ ). The mean improvement in visual acuity in alteplase-treated patients within 4.5 hours of onset was  $1.0±1.1$  logMAR versus  $0.3±0.7$  logMAR for untreated patients ( $P=0.001$ ). When the visual

recovery threshold was adjusted to 20/60 (logMAR of 0.5), 31.2% of patients treated with alteplase still met this improvement, compared with 10.8% in the untreated group ( $P=0.03$ ). Patients treated with alteplase within 4.5 hours improved at least 0.3 logMAR 56.3% of the time compared with 35.6% of untreated patients ( $P=0.12$ ). None of the patients treated with alteplase between 4.5 and 6 hours after symptom onset (0/8) recovered.

### Subject-Level Meta-Analysis

Figure 3 illustrates the selection of additional studies according to PRISMA guidelines.<sup>17</sup> Finally, we

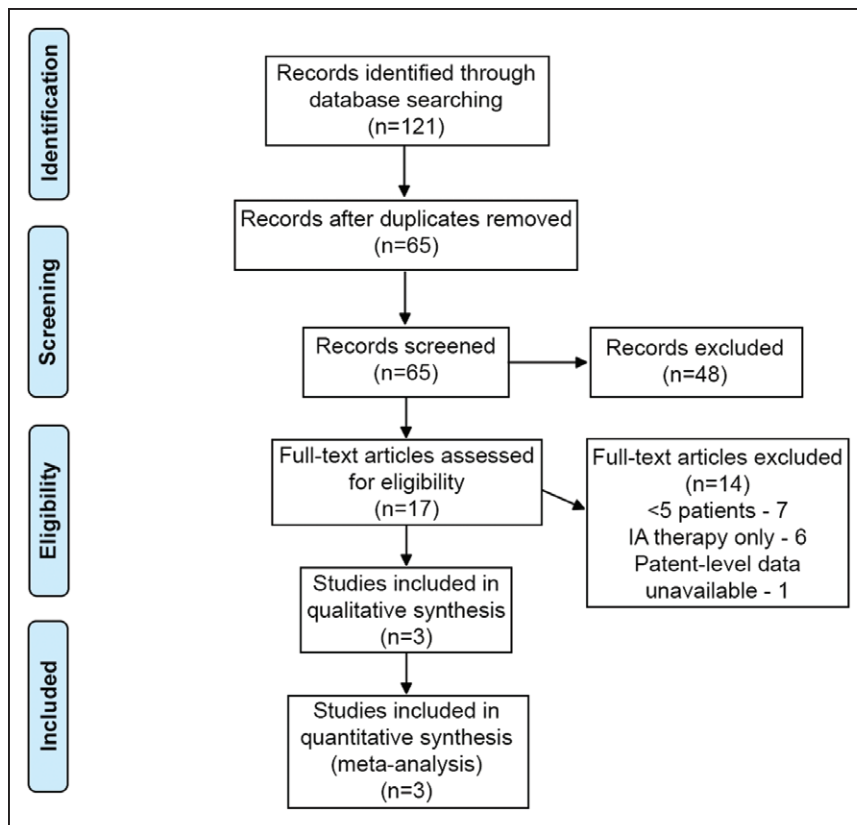


**Figure 2. Fibrinolysis at early timepoints is associated with improved visual recovery.**

**A**, Patients with acute central retinal artery occlusion (CRAO) treated with IV alteplase within 4.5 h recovered to a visual acuity of 20/100 or better (logMAR 1) 42.8% of the time compared with 11.6% of the time in patients presenting within 4 h who did not receive alteplase ( $P=0.03$ ). This was also significantly higher than the recovery rate of 12.5% in all untreated patients ( $P=0.003$ ) in our observational cohort. When combined with subject-level data from 5 other cohort studies, the result remains similar, with 37.3% recovering when treated within 4.5 h, which is considerably higher than the spontaneous recovery rate of 17.7% ( $P=0.0005$ ). **B**, Analysis of the recovery rate after any intravenous fibrinolytic treatment (alteplase, streptokinase, or urokinase) demonstrates a clear effect of time on treatment efficacy. Delay to treatment significantly predicted worse outcome in linear regression modeling corrected for age ( $P=0.01$ ). **C**, Forest plot of recovery rate in the 0 to 4.5 h window by study demonstrates a recovery rate of  $\approx 38\%$  across studies, although the effect is reduced slightly by an outlier study (Pr terre et al<sup>9</sup>), which included patients mostly late in the 4.5 h window. **D**, Change in visual acuity on the logMAR scale after alteplase treatment was similar in all studies; patients recovered by  $\approx 0.98$  logMAR. VUMC indicates Vanderbilt University Medical Center.

incorporated our results with a prior subject-level meta-analysis and those of 3 additional cohort studies<sup>8-10</sup> as well as one randomized, placebo-controlled clinical trial<sup>5</sup> into an updated subject-level meta-analysis to estimate the effect-size of alteplase treatment on visual acuity across a broader population and demonstrate the reproducibility of our findings. We are unable to formally assess publication bias due to the small number of available studies; however, we were able to obtain patient-level data for all but one study<sup>18</sup> and the current analysis represents a capture rate of 80.72% of patients in the world literature who were treated with alteplase within 4.5 hours of CRAO onset. We obtained data for 238 cases treated with any fibrinolytic agent at any time point (see Tables II and III in the [Data Supplement](#) for details

on the number of patients included per study). This group was comprised of 58.38% men and 41.62% women with a mean age of  $65.0 \pm 12.9$  years. Eighty-nine cases were treated between 0 and 4.5 hours after symptom-onset, and 38 between 4.6 and 6.0 hours. In the earlier analysis, data were available on only 34 cases treated within 4.5 hours. Data were available for 67 patients treated specifically with IV alteplase in  $<4.5$  hours—6 patients from Kattah et al,<sup>15</sup> 7 patients from Hattenbach et al,<sup>16</sup> 7 patients from Nedelmann et al,<sup>8</sup> 11 patients from Pr terre et al,<sup>9</sup> 20 patients from Schultheiss et al,<sup>10</sup> and 16 patients from our current study. The relative contribution of each study is included as Table III in the [Data Supplement](#). The mean age of patients in this group was  $69.2 \pm 12.3$  including 36.9% women and 63.1% men, and



**Figure 3. PRISMA diagram presenting the selection of additional eligible studies since 2015.**

CRAO indicates central retinal artery occlusion.



the unadjusted recovery rate was 37.3%. Only 15.2% of those treated with IV alteplase between 4.6 and 6 hours after onset recovered ( $n=28$ ,  $P=0.03$ ). The recovery rate in the early treatment group was also much higher than our estimate of the natural history of spontaneous recovery (17.7% in 396 cases;  $P=0.0005$ , Figure 2A). Using linear regression correcting for age and including patients treated with any intravenous fibrinolytic agent (alteplase, streptokinase or urokinase), time to treatment was associated with recovery rate ( $P=0.01$ , Figure 2B) and final visual acuity ( $P=0.002$ ).

After data harmonization, individual studies (that had at least 5 patients treated with alteplase within 4.5 hours) were combined in a random-effects meta-analysis weighted by the inverse of variance. This analysis slightly increased the recovery rate to 37.9% (Figure 2C) compared with the unadjusted analysis, and this effect is mediated by the presence of heterogeneity ( $Q=30.5$ ,  $P<0.0001$ ;  $i^2=83.5\%$  [95% CI, 65.7%–92.1%]). One study<sup>9</sup> reported a lower recovery rate than the others (when excluded,  $Q$  is reduced to 7.5,  $P=0.11$ ,  $i^2$  reduced to 46.7% [95% CI, 0%–80.5%]). Analysis of improvement in visual acuity on the logMAR scale across studies revealed an improvement of 0.98 ([95% CI, 0.80–1.17], Figure 2D). There was no heterogeneity in this result, and it was consistent with the result obtained from our institutional cohort.

There was a low risk of hemorrhagic complications in the included studies. There were no symptomatic intracerebral hemorrhages in patients treated within 4.5

hours since time last known well and according to standard protocols. Two symptomatic intracerebral hemorrhages occurred: one in a patient treated with both IV alteplase and therapeutic unfractionated heparin starting 4.75 hours after symptom onset and one in a patient treated with alteplase at 9.25 hours post-symptom onset (this patient was ultimately diagnosed with cerebral amyloid angiopathy). Three patients (4.5%) had asymptomatic intracerebral hemorrhage, one patient had orolingual edema and one had a hemorrhage from an undiagnosed abdominal aortic aneurysm, which did not require surgical intervention. A summary of significant adverse events is included as Table IV in the Data Supplement.

## DISCUSSION

In this study, we found that protocolized IV alteplase administration in patients with CRAO within the typical acute ischemic stroke window of 0 to 4.5 hours is feasible, safe, and is associated with a more favorable rate of visual recovery than that expected in the natural history. We include a time-matched control group who presented within 4 hours of symptom onset and who were not treated to demonstrate that the natural history is not more favorable among patients who are seen at earlier time points. Further, we supported our claim of potential efficacy of IV alteplase in patients with CRAO with a subject-level meta-analysis—a substantial update to the prior meta-analysis, which was limited by the inclusion

of various fibrinolytic agents and inconsistent administration protocols over a period of about 50 years.

CRAO results in sudden, painless loss of vision in the affected eye, which is usually permanent. In a recent poll, we found that over half of the neurologists in academic hospitals offered IV alteplase to selected patients with acute CRAO<sup>7</sup> (no centers polled as part of this poll were included in the current study). The current study found that early administration of IV alteplase after the onset of symptoms improved the rate of visual recovery compared with untreated patients and historical controls. This recovery rate is similar to that encountered in our 2015 study<sup>6</sup> and remained significantly higher in patients treated with IV alteplase, even when we conservatively changed the definition of visual recovery to include only those patients who improved above the more-stringent threshold of 20/60 (logMAR 0.5). Treatment efficacy diminishes with greater duration from the time a patient was last known well. A critically important finding from our cohort is that while the median time to ED presentation was 8 hours, the median time to the initial contact with any provider was 4 hours after onset (interquartile range, 1.5–12 hours), meaning a significant fraction of patients with acute CRAO may be candidates for fibrinolysis if they are routed efficiently to EDs capable of administering IV alteplase.

Our literature review yielded no new cases where urokinase or streptokinase were used to treat CRAO, but an abundance of studies using IV alteplase, in line with broader trends in emergency care for acute ischemic stroke. These studies consistently find a positive association of IV alteplase treatment with clinical outcomes. The lower recovery rate in Préterre et al's cohort<sup>9</sup> likely was due, at least in part, to all but one of their patients being in the 3 to 4.5 hours timeframe, where a lower response rate is anticipated. Close monitoring of outcomes in this timeframe in clinical trials will be especially important. We were unable to attain participant-level data for one study.<sup>18</sup> This study combined tissue-type plasminogen activator with anisodine (a compound that acts as a muscarinic acetylcholine receptor antagonist) in the treatment of 48 patients with CRAO. Additionally, the investigators employed a host of adjunctive therapies including nitroglycerin, methazolamide, and ocular massage. The investigators defined an "effective rate" of visual recovery as an improvement of >2 lines of visual acuity on the Snellen chart and reported this outcome in 91.67% of patients in the "treatment" group and 70.83% of patients in the "control" group. They enrolled patients at late time points including at least one patient beyond 72 hours since symptom onset. It is not clear that it would have been possible to harmonize these data with the other included studies.

Several arguments have been raised against the use of intravenous fibrinolysis for acute CRAO. The foremost concern is regarding the risk of hemorrhagic complications, particularly intracerebral hemorrhage. However, the

experience with administering alteplase in stroke mimics has demonstrated that, in the absence of cerebral ischemia, the risk of intracerebral hemorrhage is exceedingly low.<sup>19,20</sup> Approximately 30% of cases of CRAO have co-existing cerebral ischemia detected on diffusion-weighted MRI.<sup>21,22</sup> However, in the absence of overt neurological manifestations, such imaging-detected cerebral ischemia would fall within the spectrum of "minor stroke"—a condition in which adverse events related to IV alteplase administration is also very low (2%–2.4% of cases)<sup>23,24</sup> and in which the rate of fatal intracranial hemorrhage is 0.9%.<sup>25</sup> Furthermore, our continuing experience with IV alteplase specifically in the context of acute CRAO suggests that, when given as part of a protocol and without the adjuvant use of systemic anticoagulation (as was used in some of the earlier studies), it is associated with a low risk of intracranial hemorrhage.

Our observational study is limited by the lack of randomization of treatment and thus we cannot exclude systematic difference between those patients who received fibrinolysis and those who did not. For instance, patients treated with fibrinolysis had a lower visual acuity on presentation than those not treated with thrombolysis (logMAR 2.5±0.3 versus 2.1±0.6), which should lead to a bias against a treatment effect. There are limitations inherent in meta-analysis of predominantly observational studies. The analysis is limited by the presence of only one, small placebo-controlled clinical trial in the world literature and combining observational and randomized data in one analysis is a limitation (although the relative contribution from the one, small clinical trial was minimal). The high recovery rate in those treated with alteplase within 4.5 hours of may be in part explained by spontaneous lysis of the occluding thrombus, that is, this group may have included patients who would otherwise have had amaurosis fugax. However, we included an analysis of patients presenting within 4 hours and who did not receive alteplase and found that the treatment effect of alteplase was a durable one. This work is also somewhat limited by the potential for selection bias, which has the possibility of biasing the results in favor of treatment. We excluded studies with fewer than 5 subjects to reduce the risk of selection bias.

## CONCLUSIONS

This study provides key foundational data to support conducting clinical trials with intravenous fibrinolysis in patients with acute CRAO. A clinical trial comparing intravenous thrombolysis using alteplase versus placebo within 4.5 hours of symptom onset is warranted, and we think it should take the form of a pragmatic, multicenter, randomized, placebo-controlled, double-blinded study. The current study allows a more precise estimate of the treatment effect and thus will aid with sample size and power calculations. Our data add to the growing body of evidence that indicates it may be effective and safe. As stroke systems

of care evolve, protocols for identification, triage, and rapid treatment of CRAO should be incorporated.

## ARTICLE INFORMATION

Received December 16, 2019; final revision received April 13, 2020; accepted May 6, 2020.

### Affiliations

Department of Neurology (B.M.G., C.S., I.A., J.P., T.B., K.F.) and Division of Ophthalmology, Department of Surgery (T.B.), Warren Alpert Medical School of Brown University, Providence, RI. Department of Neurology (A.N., P.L., E.M., K.E., H.K., M.S.) and Department of Ophthalmology and Visual Sciences (P.L.), Vanderbilt University School of Medicine, Nashville, TN. Department of Neurology with Focus on Neurovascular Diseases, and Hertie Institute for Clinical Brain Research, University Hospital Tübingen, Germany (S.P.). Eye Clinic, University Hospital Hamburg-Eppendorf, Germany (M.S.S.). Department of Neurology, Sana Regio Klinikum, Pinneberg, Germany (M.N.). Department of Neurology, CHU de Nantes – Laennec Nantes, France (B.G., C.P.). Department of Ophthalmology, Flinders Medical Center and Flinders University, Adelaide, Australia (C.S.C.). Department of Neurology, Flinders University and the Calvary Wakefield Hospital, Adelaide, Australia (A.W.L.). Department of Neurology, New York University School of Medicine (S.Y.). Massachusetts Eye and Ear Infirmary, Harvard Medical School, Boston (T.B.). Department of Neurology, Boston University School of Medicine, MA (D.M.G., J.G.S.). Department of Neurology, Henry Ford Hospital, Detroit, MI (R.G.K.).

### Disclosures

Dr. Nackenoff reports receiving grant funding from the NIH (T32AG058524). Dr. Spitzer reports receiving grant funding from Novartis, Alcon, Croma Pharmaceuticals and IDx as well as consulting fees from Novartis, Bayer, Altacor, Ltd, Oxurion, Geuder and Aliemera Sciences. Dr. Guillon reports personal fees from BMS and Boehringer-Ingelheim outside the submitted work. Dr. Yaghi receives departmental funding from Medtronic Inc. for outcome adjudication in an industry-sponsored study. Dr. Stretz received a travel grant from the Neurocritical Care Society to attending the 2017 Neurocritical Care Society Annual Meeting. Dr. Mistry reports receiving grant funding from the Society of Vascular and Interventional Neurology, the University of Cincinnati Gardner Neuroscience Institute, the Vanderbilt Faculty Research Scholars Program and the NINDS (K23NS113858). Dr. Schrag receives grant funding from the NIA (K76AG060001) and NINDS (R03NS111486 and R21NS106510). The other authors report no conflicts.

## REFERENCES

- Sacco RL, Kasner SE, Broderick JP, Caplan LR, Connors JJ, Culebras A, Elkind MSV, George MG, Hamdan AD, Higashida RT, et al; American Heart Association Stroke Council, Council on Cardiovascular Surgery and Anesthesia; Council on Cardiovascular Radiology and Intervention; Council on Cardiovascular and Stroke Nursing; Council on Epidemiology and Prevention; Council on Peripheral Vascular Disease; Council on Nutrition, Physical Activity and Metabolism. An updated definition of stroke for the 21<sup>st</sup> century: a statement for healthcare professionals from the American Heart Association/American Stroke Association. *Stroke*. 2013;44:2064–2089. doi: 10.1161/STR.0b013e318296aeca
- Rossmann H. [The thrombolytic therapy of vascular occlusions of the retina]. *Klin Monbl Augenheilkd*. 1966;149:874–880.
- Kamei H, Matsuhashi H, Yoshimoto H. Therapy and visual prognosis in retinal artery occlusion. *Nippon ganka kiyo*. 1985;36:2279–2284.
- The national institute of neurological disorders and stroke rt-pa stroke study group. Tissue plasminogen activator for acute ischemic stroke. *N Engl J Med*. 1995;333:1581–1587.
- Chen CS, Lee AW, Campbell B, Lee T, Paine M, Fraser C, Grigg J, Markus R. Efficacy of intravenous tissue-type plasminogen activator in central retinal artery occlusion: report from a randomized, controlled trial. *Stroke*. 2011;42:2229–2234. doi: 10.1161/STROKEAHA.111.613653
- Schrag M, Youn T, Schindler J, Kirshner H, Greer D. Intravenous fibrinolytic therapy in central retinal artery occlusion: a patient-level meta-analysis. *JAMA Neurol*. 2015;72:1148–1154. doi: 10.1001/jamaneurol.2015.1578
- Youn TS, Lavin P, Patrylo M, Schindler J, Kirshner H, Greer DM, Schrag M. Current treatment of central retinal artery occlusion: a national survey. *J Neurol*. 2018;265:330–335. doi: 10.1007/s00415-017-8702-x
- Nedelmann M, Graef M, Weinand F, Wassill KH, Kaps M, Lorenz B, Tanislav C, et al. Retrobulbar spot sign predicts thrombolytic treatment effects and etiology in central retinal artery occlusion. *Stroke*. 2015;46:2322–2324. doi: 10.1161/STROKEAHA.115.009839
- Préterre C, Godeneche G, Vandamme X, Ronzière T, Lamy M, Breuille C, Urbanczyk C, Wolff V, Lebranchu P, Sevin-Allouet M, et al. Management of acute central retinal artery occlusion: intravenous thrombolysis is feasible and safe. *Int J Stroke*. 2017;12:720–723. doi: 10.1177/1747493016687578
- Schultheiss M, Härtig F, Spitzer MS, Feltgen N, Spitzer B, Hüsing J, Rupp A, Ziemann U, Bartz-Schmidt KU, Poli S, et al. Intravenous thrombolysis in acute central retinal artery occlusion – A prospective interventional case series. *PLoS One*. 2018;13:e0198114. doi: 10.1371/journal.pone.0198114
- Hacke W, Kaste M, Bluhmki E, Brozman M, Dávalos A, Guidetti D, Larrue V, Lees KR, Medeghri Z, Machnig T, et al; ECASS Investigators. Thrombolysis with alteplase 3 to 4.5 hours after acute ischemic stroke. *N Engl J Med*. 2008;359:1317–1329. doi: 10.1056/NEJMoa0804656
- Lange C, Feltgen N, Junker B, Schulze-Bonsel K, Bach M. Resolving the clinical acuity categories “hand motion” and “counting fingers” using the Freiburg Visual Acuity Test (FrACT). *Graefes Arch Clin Exp Ophthalmol*. 2009;247:137–142. doi: 10.1007/s00417-008-0926-0
- Campbell I. Chi-squared and fisher-inwin tests of two-by-two tables with small sample recommendations. *Stat Med*. 2007;26:3661–3675. doi: 10.1002/sim.2832
- Stroup DF, Berlin JA, Morton SC, Olkin I, Williamson GD, Rennie D, Moher D, Becker BJ, Sipe TA, Thacker SB, et al. Meta-analysis of observational studies in epidemiology: a proposal for reporting. Meta-analysis Of Observational Studies in Epidemiology (MOOSE) group. *JAMA*. 2000;283:2008–2012. doi: 10.1001/jama.283.15.2008
- Kattah JC, Wang DZ, Reddy C. Intravenous recombinant tissue-type plasminogen activator thrombolysis in treatment of central retinal artery occlusion. *Arch Ophthalmol*. 2002;120:1234–1236.
- Hattenbach LO, Kuhli-Hattenbach C, Scharrer I, Baatz H. Intravenous thrombolysis with low-dose recombinant tissue plasminogen activator in central retinal artery occlusion. *Am J Ophthalmol*. 2008;146:700–706. doi: 10.1016/j.ajo.2008.06.016
- Moher D, Liberati A, Tetzlaff J, Altman DG; PRISMA Group. Preferred reporting items for systematic reviews and meta-analyses: the PRISMA statement. *PLoS Med*. 2009;6:e1000097. doi: 10.1371/journal.pmed.1000097
- Wu XJ, Gao F, Liu X, Zhao Q. Observation on therapeutic efficacy of rt-PA intravenous thrombolysis combined with compound anisodine injection on central retinal artery occlusion. *Exp Ther Med*. 2016;12:2617–2621. doi: 10.3892/etm.2016.3681
- Zinkstok SM, Engelter ST, Gensicke H, Lyrer PA, Ringleb PA, Artto V, Putaala J, Haapaniemi E, Tattisumak T, Chen Y, et al. Safety of thrombolysis in stroke mimics: results from a multicenter cohort study. *Stroke*. 2013;44:1080–1084. doi: 10.1161/STROKEAHA.111.000126
- Keselman B, Cooray C, Vanhooren G, Bassi P, Consoli D, Nichelli P, Peeters A, Sanak D, Zini A, Wahlgren N, et al. Intravenous thrombolysis in stroke mimics: results from the SITS international stroke thrombolysis register. *Eur J Neurol*. 2019;26:1091–1097. doi: 10.1111/ene.13944
- Helenius J, Arsava EM, Goldstein JN, Cestari DM, Buonanno FS, Rosen BR, Ay H. Concurrent acute brain infarcts in patients with monocular visual loss. *Ann Neurol*. 2012;72:286–293. doi: 10.1002/ana.23597
- Lavin P, Patrylo M, Hollar M, Espaillet KB, Kirshner H, Schrag M. Stroke risk and risk factors in patients with central retinal artery occlusion. *Am J Ophthalmol*. 2018;196:96–100. doi: 10.1016/j.ajo.2018.08.027
- Yeo LLL, Ho R, Paliwal P, Rathakrishnan R, Sharma VK. Intravenously administered tissue plasminogen activator useful in milder strokes? A meta-analysis. *J Stroke Cerebrovasc Dis*. 2014;23:2156–2162. doi: 10.1016/j.jstrokecerebrovasdis.2014.04.008
- Shi L, Zhang M, Liu H, Song B, Song C, Xu Y. Safety and outcome of thrombolysis in mild stroke: a meta-analysis. *Med Sci Monit*. 2014;20:2117–2124. doi: 10.12659/MSM.892259
- Embersson J, Lees KR, Lyden P, Blackwell L, Albers G, Bluhmki E, Brott T, Geoff Cohen G, Davis S, Donnan G, et al; Stroke Thrombolysis Trialists' Collaborative Group. Effect of treatment delay, age, and stroke severity on the effects of intravenous thrombolysis with alteplase for acute ischaemic stroke: a meta-analysis of individual patient data from randomised trials. *Lancet*. 2014;384:1929–1935. doi: 10.1016/S0140-6736(14)60584-5